

Extraction of Epi-cardium contours from unseen images using a shape database

Michael Lynch
Vision Systems Group
Dublin City University
Dublin 9, Ireland
Email: lynchm@eeng.dcu.ie
Telephone : +353-1-700-7637

Ovidiu Ghita
Vision Systems Group
Dublin City University
Dublin 9, Ireland

Paul F. Whelan
Vision Systems Group
Dublin City University
Dublin 9, Ireland

Abstract—Accurate segmentation of the myocardium in cardiac magnetic resonance images can be restricted by image noise and low discrimination between the epi-cardium boundary and other organs. Segmentation of the epi-cardium is important for the calculation of left ventricle mass.

In this paper we propose a novel method of epi-cardium segmentation which firstly segments the left ventricle cavity. The epi-cardium boundary is found using the edge information in the image, and where such information is lacking it enhances the shape with the best fitting scaled segment, taken from a database of expertly assisted hand segmented images. In the final stage the segments are connected using a natural closed spline.

The method was evaluated using a leave-one-out strategy on 24 volumes and calculates the coefficient of determination as 0.93 and a root mean square of the point to curve error of 1.54mm when compared to manually segmented images.

I. INTRODUCTION

Cardiac Magnetic Resonance (CMR) has become an important tool for the prognosis and treatment monitoring of cardiovascular disease (CVD). CMR is preferred due to its short acquisition time, < 10 minutes for ECG-gated cine CMR or < 10 seconds for the newest scanners where the cine stack can be obtained in a single breath hold [1]. In addition to the fast acquisition time, the patient is not exposed to high degrees of radiation as is the case in Computer Tomography (CT).

CMR is considered by some to be the reference standard for the measurement of the left ventricle volume (LVV) and left ventricle mass (LVM) [2], [3]. The left ventricle volume is used in the calculation of the ejection fraction (EF), which is a standard medical indicator of a hearts state of health. The LVM can flag an enlargement of the ventricular muscle (hypertrophy) and can a predictor for increased risk of cardiovascular mortality and morbidity [1]. The position and extent of systolic wall thickening are also useful in the assessment of ischemic heart disease.

The increased volume of data generated by the latest CMR scanners presents a vast amount of high resolution volumetric data to the specialist. Interpreting and analyzing this large amount of data represents a tedious and time-consuming task

for the cardiologist. Manual delinearisation is still a prominent method used to segment the left ventricle myocardium. Since manual segmentation is labour-intensive, time-consuming and suffers from inter- and intra-observer variability, the prospect of an automatic and accurate segmentation is highly desirable. Automatic segmentation will therefore enhance comparability between and within cardiac studies and increase accurate evaluation of volumes by allowing acquisition of thinner MRI-slices. For this reason segmentation of the left ventricle from CMR images is necessary for finding all these measurements and therefore is an area of on-going research [4], [5].

Semi-automated methods have being developed which usually requires a lot of interaction and intervention by the user. This reduces the time involved in the segmentation but still suffers from inter- and intra-observer variability. Low-level operations such as thresholding have also being investigated [6].

Much literature has being written on model based segmentation approaches [4]. Known problems associated with model based approaches are their failure or attraction to erroneous points in areas of low contrast like those found between the epi-cardium and the lungs. The accuracy of the segmentation relies heavily on the amount and variation of images in the training set. If the training set is too small with small variation, there is a limited number of unseen images that the model is applicable too. If, on the other hand, the model is large with large variation it may choose some erroneous points. Convergence is defined by the step-to-step changes in shape, scale, rotation, and position falling below a tolerance value.

A method is proposed which uses the low level information in the image where it is available. Where such information it is not available it uses a model that has being built up from previously hand-segmented images. The finished segmentation contains actual information obtained from the image and appends it with *a priori* knowledge where necessary.

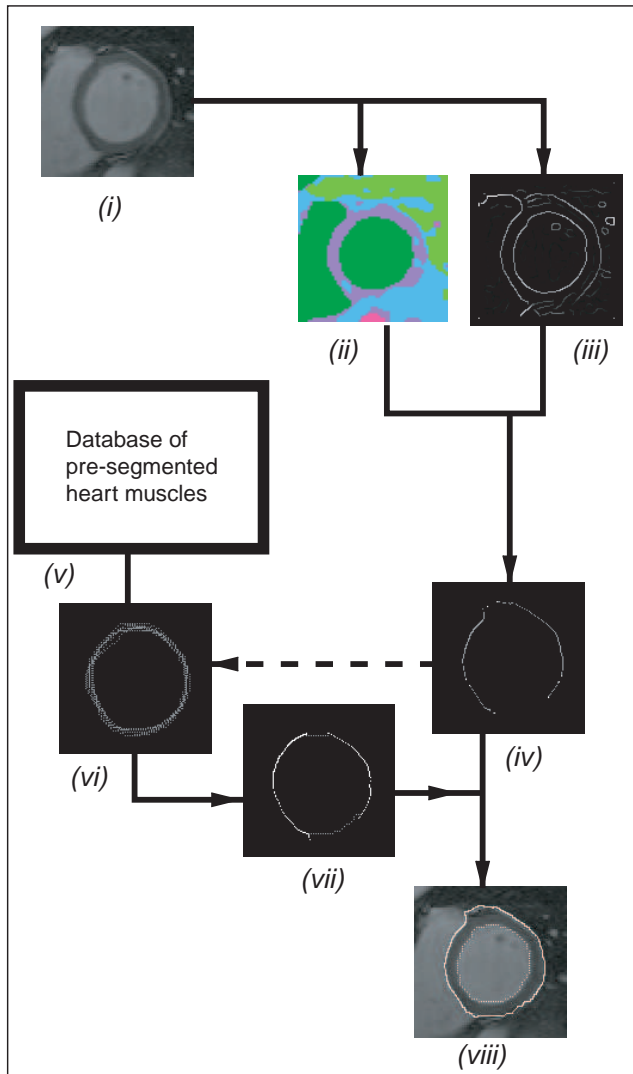


Fig. 1. Shows the segmentation scheme from the original image (i) to the complete segmented epi-cardium boundary (viii)

This paper is presented as follows; section 2 describes the methods involved in the segmentation, firstly a brief description of how the left ventricle cavity is obtained. We then move on to explain how the valid segments from the epi-cardium are found and how these segments are used to obtain the best fitting model from the database. Finally, results are presented for the segmentation against manually segmented images with some final conclusions.

II. METHOD

The search for the epi-cardium border starts with the segmentation of the left-ventricle cavity. This is achieved by smoothing the 2D slices using a diffusion-based filter [7]. The use of nonlinear diffusion-based filters has been investigated for use in medical images and in particular CMR. In their formulation, the blurring would be performed within homogeneous image regions with no interaction

between adjacent or neighbouring regions that share a common border. The non-linear diffusion procedure can be written in terms of the derivative of the flux function, $\phi(\nabla I) = \nabla I \cdot D(\|\nabla I\|)$, where ϕ is the flux function, I is the image and D is the diffusion function. This equation is implemented in an iterative manner to obtain improved results.

Segmentation of the left ventricle cavity is achieved by clustering the image, see figure 1 (ii). The clustering is performed on the 3D volume using an unsupervised k-means clustering technique [8], which classifies pixels into groups or clusters using a distance criteria to join data values to each cluster. The process then moves the elements between clusters with two aims,

- (i) to minimise the variation within each cluster and
- (i) to maximise the variation between clusters

The process terminates when no more elements are exchanged between clusters and is convergent.

Once the endo-cardium border has been successfully delineated, the second step is to find the epi-cardium border. The algorithm is a 2D approach working on the individual slices from the volume. Once each slice is taken from the volume the centre of gravity of the left ventricle blood pool is located and the least squares approximation for the radius of the endo-cardium border is calculated. By re-clustering the image again around a smaller region of interest with a set low number of clusters in order to find the right ventricle blood pool. The right ventricle blood pool is found to be the largest cluster, close to the left ventricle cavity with similar attributes to the left ventricle blood pool. Once the right ventricle blood pool has being located, the myocardium wall (*interventricular septum*) between the two ventricles is measured. This measurement gives an approximate thickness for the myocardium around the left ventricle.

A non-maximum suppression edge-detector is used on the original image slice, see figure 1 (iii). A radial search is performed of the gradient image from the centre of gravity of the left ventricle cavity to determine possible epi-cardium edges. From this gradient image, edge points are connected together into edge segments using a Euclidean distance criterion. Spurious segments are eliminated by length, by orientation away from the endo-cardium border and using the approximation for the myocardium from the *interventricular septum*. The remaining segments are shown in figure 1 (iv).

Between the segments are gaps where there is no distinguishable gradient between the myocardium and the other organs. Therefore there is no other information in the image to help find the correct path between these segments. In this case *a priori* knowledge about the shape obtained from previously hand-segmented can be used to join the segments. In this way we introduce a type of supervision, and by inferring expertly drawn contours we maintain continuity of the shape. Because the contour maintains its original segments, the manually

drawn contours are only inferred where there is no information to be found in the image. We believe that this is a more appropriate solution as when complete models are inferred onto the image there is a danger that details may be lost.




Fig. 2. Figure shows four images, (a) Original unseen image, (b) calculated edges, (c) robust segments of epi-cardium and (d) the complete segmentation

Appropriate shapes are selected from the database using the radius least mean squares approximation for both the endo-cardium and the epi-cardium segments. The database is searched for shapes that fall within a threshold 10% of these radii. The shapes are then translated to the correct spatial position using the centre of gravity of the left ventricle cavity, see figure 1 (vi).

Once the list of appropriate shapes has been extracted from the database the next step is to close the segments of the epi-cardium shape using the best fitting database entry. For every two segments, the deviation is calculated for each of the shapes in the database list. The shape with the minimum deviation is chosen and the appropriate points from the database shape are used to fill the between the segments. This is completed for every two segments and the first and final segments. The points on the epi-cardium shape are then joined using a natural cubic closed spline of order three, see figure 1 (viii).

III. RESULTS

An evaluation of the results was made using 24 volume images taken from patient transversing the left ventricle from the base to the apex along the short axis. The imaging device was a Siemens Magnetom Sonata 1.5 Tesla, $TR = 3.2$, $TE = 1.6$, cine acquisition with TrueFISP balancing at a resolution of (1.37x1.37x 8mm).

The volumes were assessed using a leave-one-out strategy, with the model containing the information for 23 volumes and evaluation performed on the unseen volume. Figure 3(a) shows the Bland-Altman plot which indicates good reproducibility with this method, secondly a linear graph, figure 3(b) is plotted and gives an r^2 of 0.93.

The point to curve measurement is the Euclidean distance from each point in the automatically delineated boundary to the closest point on the manual delineated boundary. The value of the root mean square of the standard deviation for 150 slices was 1.54mm.

IV. CONCLUSION

This paper describes a novel approach for the delinerisation of the epi-cardial boundary of the left ventricle. The algorithm uses all the available information within the images, but where there is no useful information present the algorithm searches a database for appropriate segments.

Due to the low contrast in some areas of the images that separate the epi-cardium from other organs in the body, a good correlation between segmentations is extremely hard to accomplish even between expert tracings. Inter- and Intra-observer variability is very high for the delineation of the epi-cardial boundary and knowledge and expertise of the cardiologist is a major factor. This is one of the main reasons for implementing a database model from hand-segmented images. Other deformable model approaches aim find strong gradient features of the epi-cardial boundary and from this information find the model instance that fits with the least amount of error. However the model-assisted algorithm presented here enhances the strong features of the epi-cardial boundary already found in the image with the most appropriate segment from the hand-annotated images to reduce the error while maintaining continuity of the curve. This method presents a robust segmentation of the epi-cardial boundary even in the presence of low contrast between the myocardium and other organs.

REFERENCES

- [1] S. G. Myerson, N. G. Bellenger, and D. J. Pennell, "Assessment of left ventricular mass by cardiovascular magnetic resonance," *Hypertension*, vol. 39, pp. 750–755, 2002.
- [2] M. Dulce and G. Mostbeck, "Quantification of the Left Ventricular Volumes and Function with Cine MR Imaging: Comparison of Geometric Models with Three-Dimensional Data," *Radiology*, vol. 188, no. 371–376, 1993.
- [3] S. Schalla, E. Nagel, H. Lehmkuhl, C. Klein, A. Bornstedt, B. Schnackenburg, U. Schneider, and E. Fleck, "Comparison of Magnetic Resonance Real-Time Imaging of Left Ventricular Function with Conventional Magnetic Resonance Imaging and Echocardiography," *The American Journal of Cardiology*, vol. 87, no. 1, pp. 95–99, 2001.
- [4] F. Frangi *et al.*, "Three-Dimensional Modelling for Functional Analysis of Cardiac Images: A Review," *IEEE Transactions on Medical Imaging*, vol. 20, no. 1, 2001.
- [5] R. J. van der Geest and J. Reiber, *Cardiovascular MRI and MRA*. Philadelphia: Lippincott, Williams and Wilkins, 2003, ch. 5.

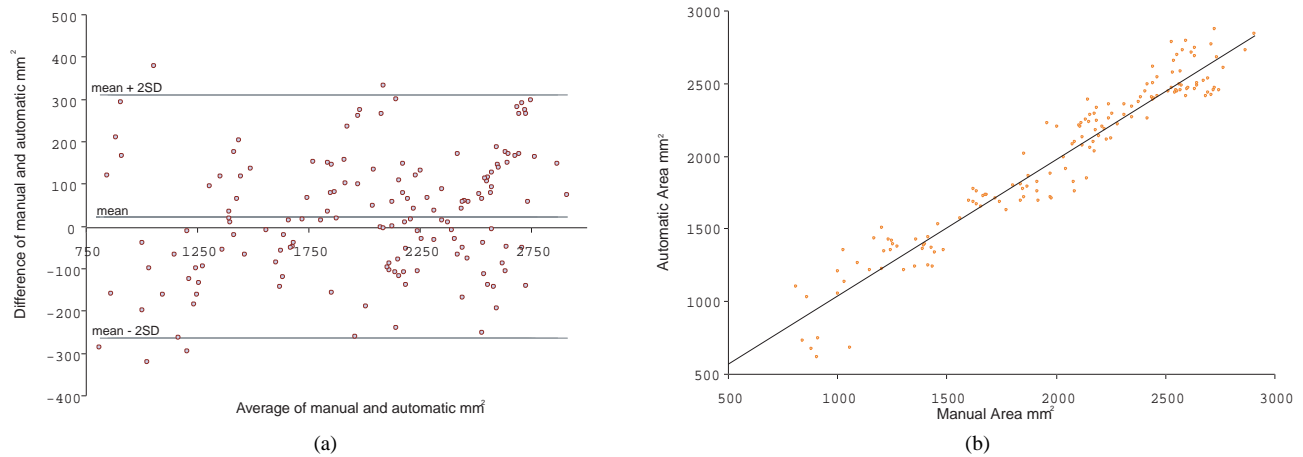


Fig. 3. Figures (a)-(b) show the Bland-Altman and the scatterline plot of manual segmentation against the automatic segmentation for the epi-cardium areas.

- [6] J. Suri, "Computer Vision, Pattern Recognition and Image Processing in Left Ventricle Segmentation: The Last 50 Years," *Pattern Analysis and Applications*, vol. 3, no. 3 2000, pp. 209–242, 2000.
- [7] P. Perona and J. Malik, "Scale-space and edge detection using anisotropic diffusion," *IEEE Trans. on Pattern Analysis and Machine Intelligence*, vol. 12, no. 7, pp. 629–639, 1990.
- [8] R. Duda and P. Hart, *Pattern Classification and Scene Analysis*. NY: Wiley, 1973.